



SKIN^OPATHY

ACNE DATA & AI


Accessible
Inclusive
Dermatology
Everywhere

A person wearing a white lab coat and a stethoscope is holding a tablet computer. The background is a clinical setting with various medical equipment and papers. The image has a blue and orange color overlay.

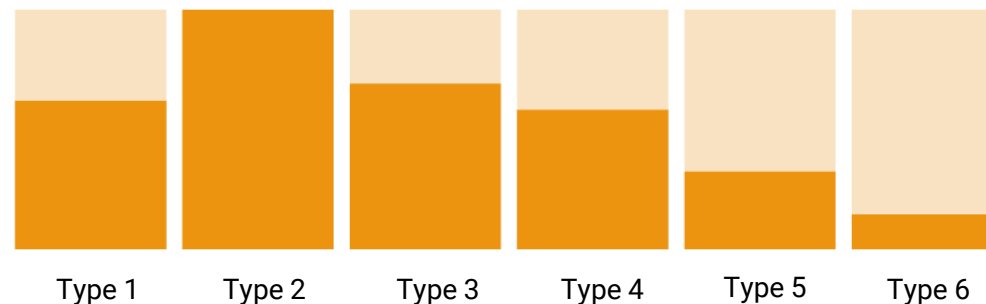
**For All
Skin Types**

Augment AI Data for Equitable Skin Tone Sensitivity

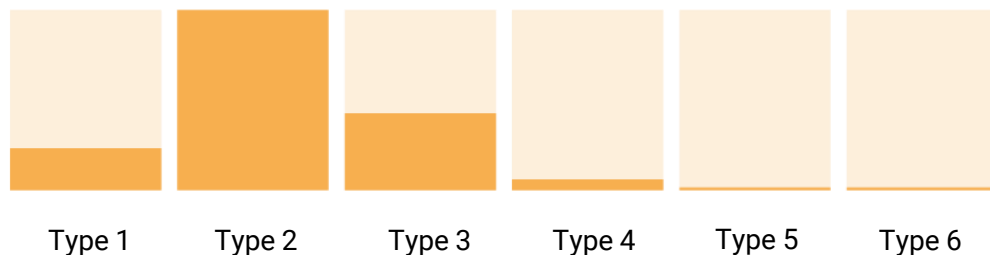
A Fitzpatrick Skin tone Scale



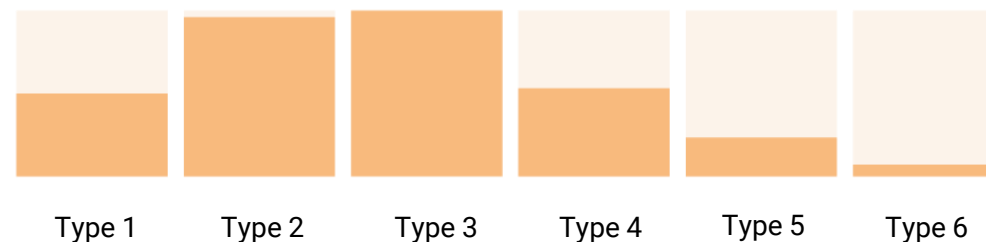
B Skin Benchmark Dataset



C Original Skinopathy Skin conditions Dataset

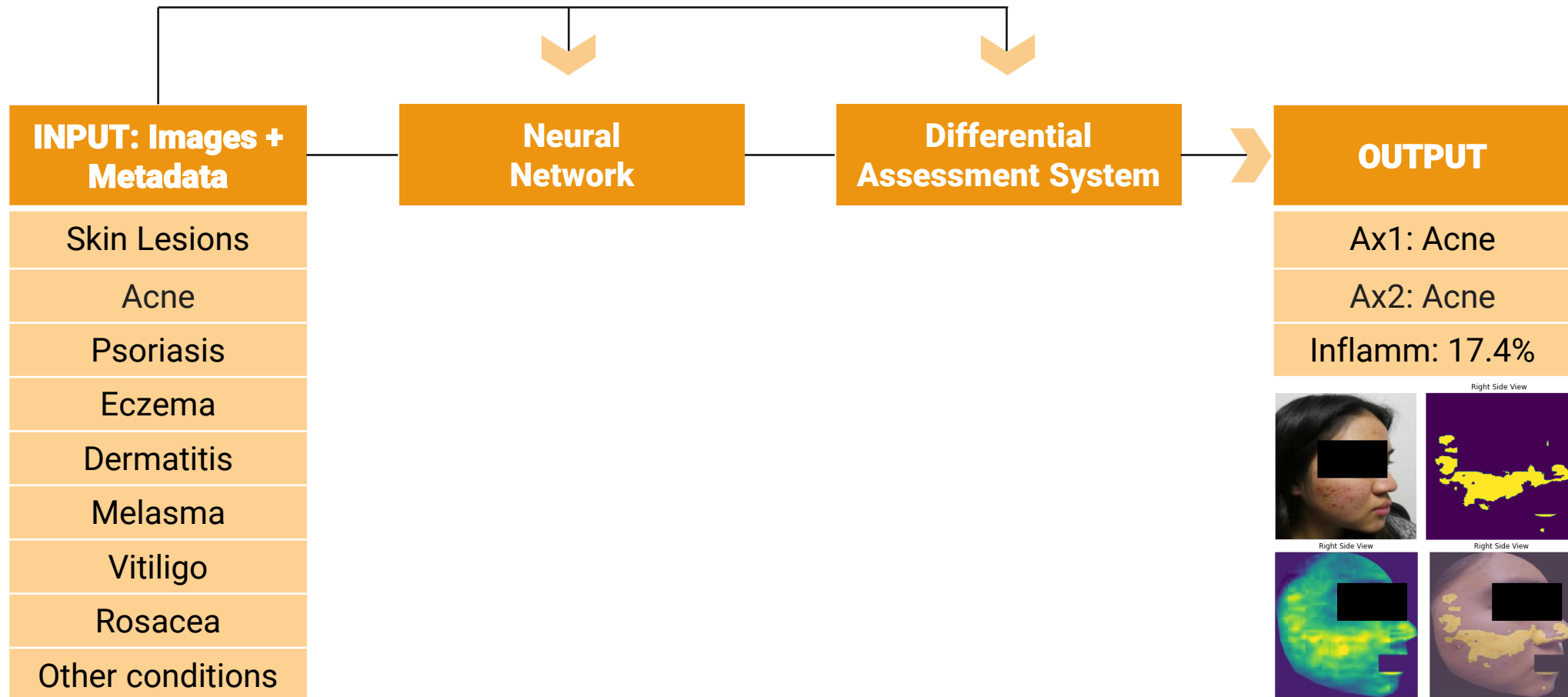


D Augmented Dataset Using AI / ML



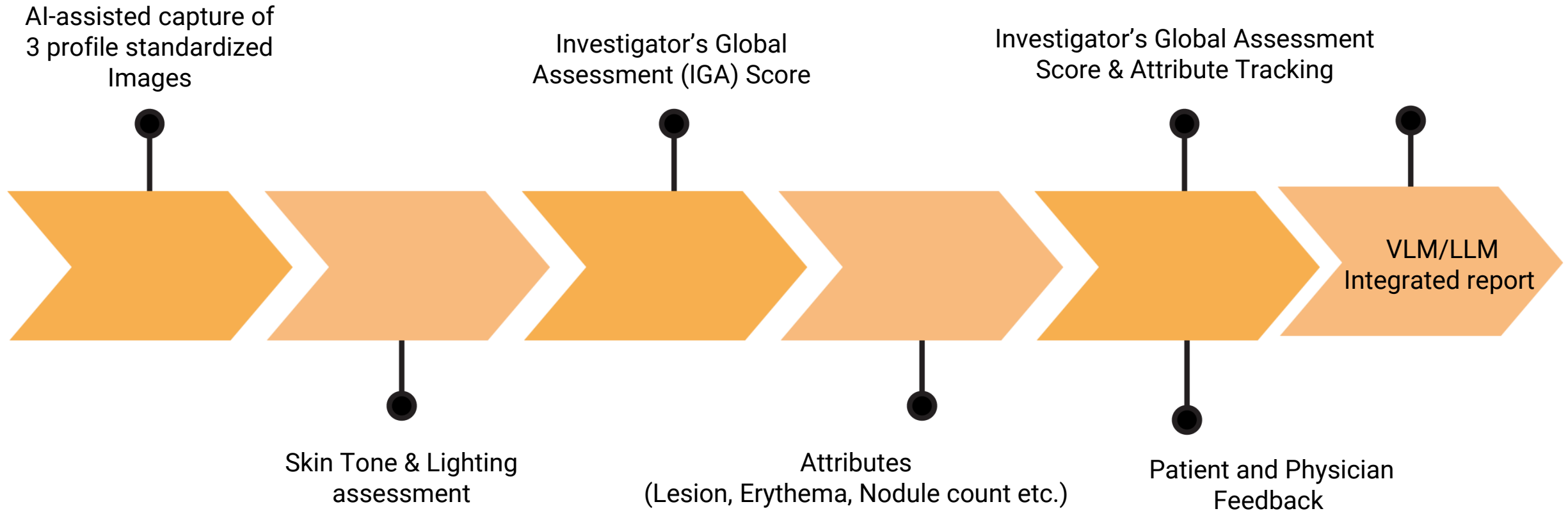
(Mhedbi et al, 2023)

Skinopathy AI Model




A Machine Learning pipeline utilizing neural network and non-probabilistic and LLM models for differential assessment of dermatological conditions

Image-Based Assessments for Acne




Automated 3-profile Image Capture

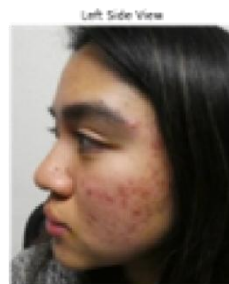Acne App Camera



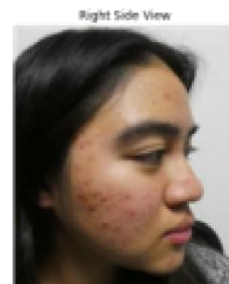Front



Left




Right

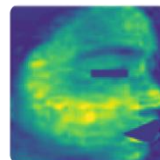
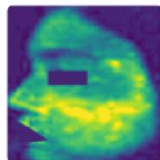


Colorimetric
Algorithm

Inflammation:
%23.58



%23.23



%15.14

Deep
CNN

Front

Moderate-
Severe


Left

Moderate-
Severe

Right


Mild-
Moderate

Baseline Skin Tone from an Image: **Monk Scale** Provides Finer-grained Delineation & Assessment Equity than ITA



	Precision	Recall	+1 - Score	Support
MST_1	1.00	0.97	0.99	36
MST_2	1.00	0.83	0.91	42
MST_3	0.94	0.83	0.88	18
MST_4	1.00	0.71	0.83	38
MST_5	0.69	1.00	0.82	36
MST_6	0.78	0.97	0.86	33
MST_7	0.94	1.00	0.97	15
MST_8	1.00	0.93	0.96	28
MST_9	0.93	0.93	0.93	28
MST_10	1.00	0.91	0.95	22
Accuracy			0.90	236
Macro Avg	0.93	0.91	0.91	236
Weighted Avg	0.92	0.90	0.90	236

Colorspace Colorimetry (m-ITA) & Monk Skin Tone – Equitable AI & Light/Shadow Control



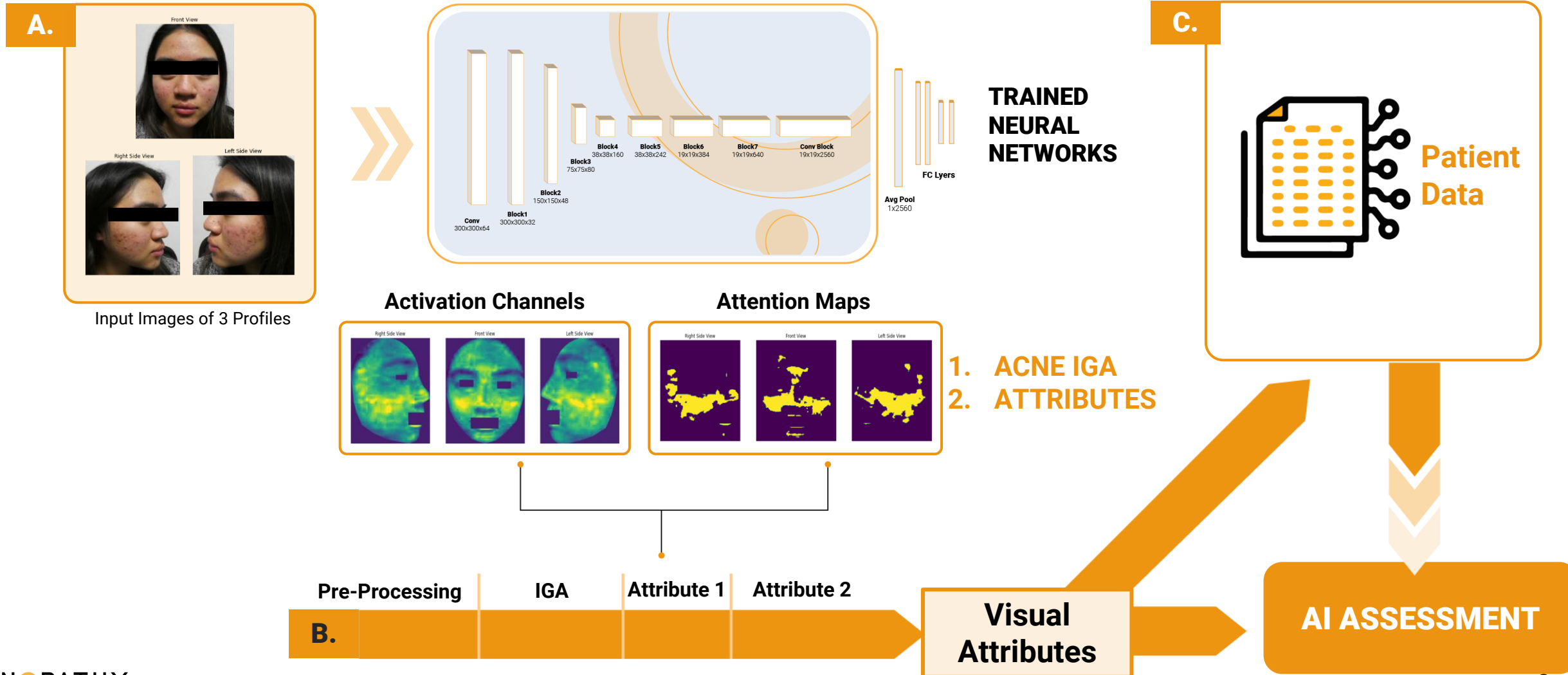
Fitzpatrick Scale



Monk Scale



Multi-Modal AI Pipeline to Assess IGA & Visual Attributes of Facial Acne




What is the Investigator Global Assessment (IGA) Score?

“A measure of acne severity that **has been used in clinical trials** and controlled experimental studies since it was approval by the US FDA in 2005”

- A Comprehensive Review of the Acne Grading Scale in 2023, Annals of Dermatology


0 – Clear	Clear skin with no inflammatory or noninflammatory lesions
1 – Almost Clear	Rare noninflammatory lesions with more than one small inflammatory lesion
2 – Mild	Greater than grade 1; some noninflammatory lesions with no more than a few inflammatory lesions (papules/pustules only, no nodular lesions)
3 – Moderate	Greater than grade 2; up to many noninflammatory lesions and may have some inflammatory lesions, but no more than one small nodular lesion
4 – Severe	Greater than grade 3; up to many noninflammatory and inflammatory lesions, but no more than a few nodular lesions
5 – Very Severe	Greater than grade 4; many non-inflammatory and inflammatory lesions and more than a few nodular lesions. May have cystic lesions

IGA & Specific Visual Attributes – Real World Evidence




Acne Severity (IGA 2-4) & Erythema Tracking by Face Profile

Jan 2022




Moderate	Moderate	Mild
%4.24	%4.24	%2.36

Feb 2022




Mild	Severe	Severe
%3.21	%3.89	%5.34

May 2022



Mild	Moderate	Severe
%3.82	%3.54	%5.87

June 2022

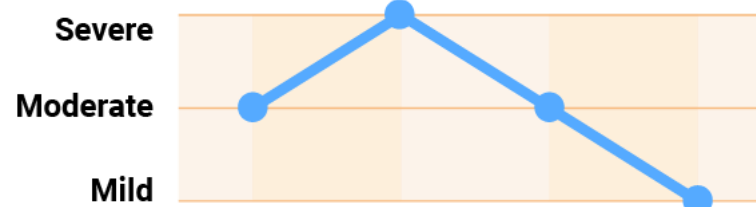

Mild	Mild	Moderate
%2.79	%4.72	%1.77

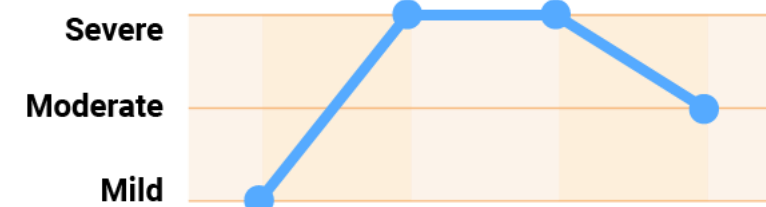Front



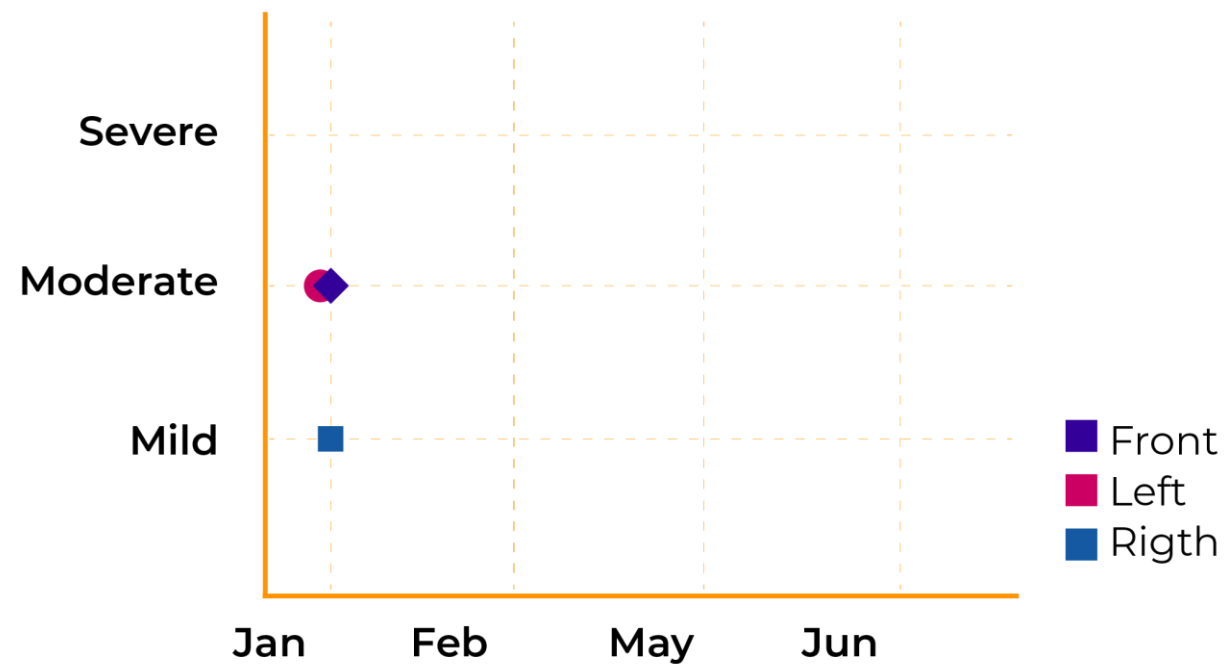

Left



Right

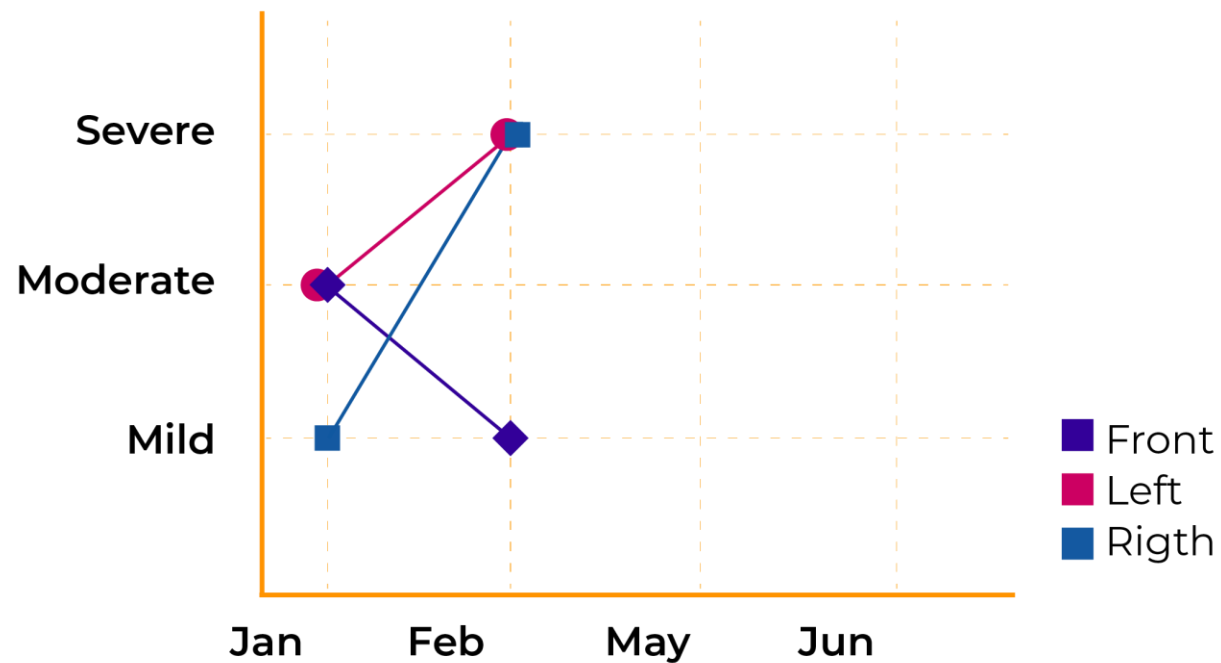
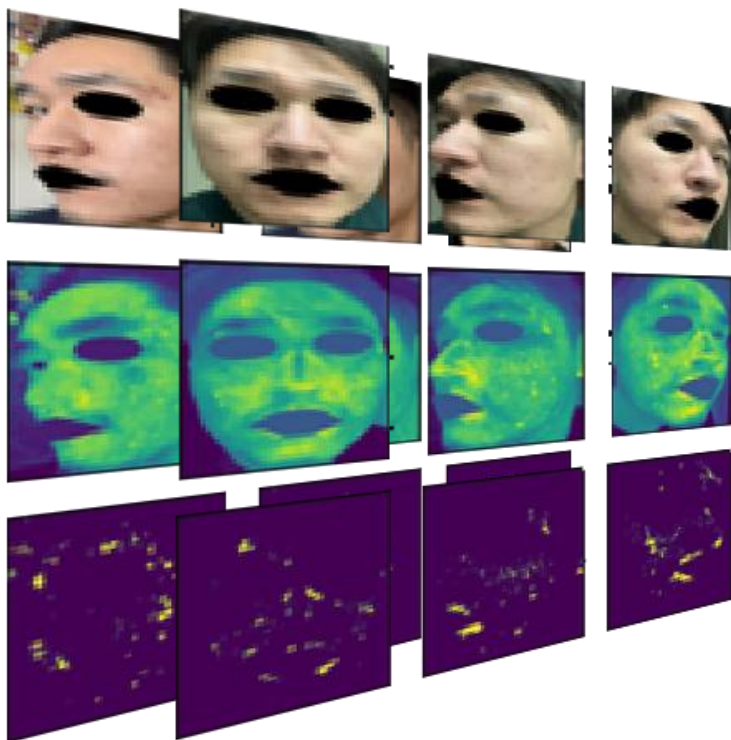


Tracking Acne Progress



Jan 2022 **Moderate** %4.24 **Moderate** %4.24 **Mild** %2.36

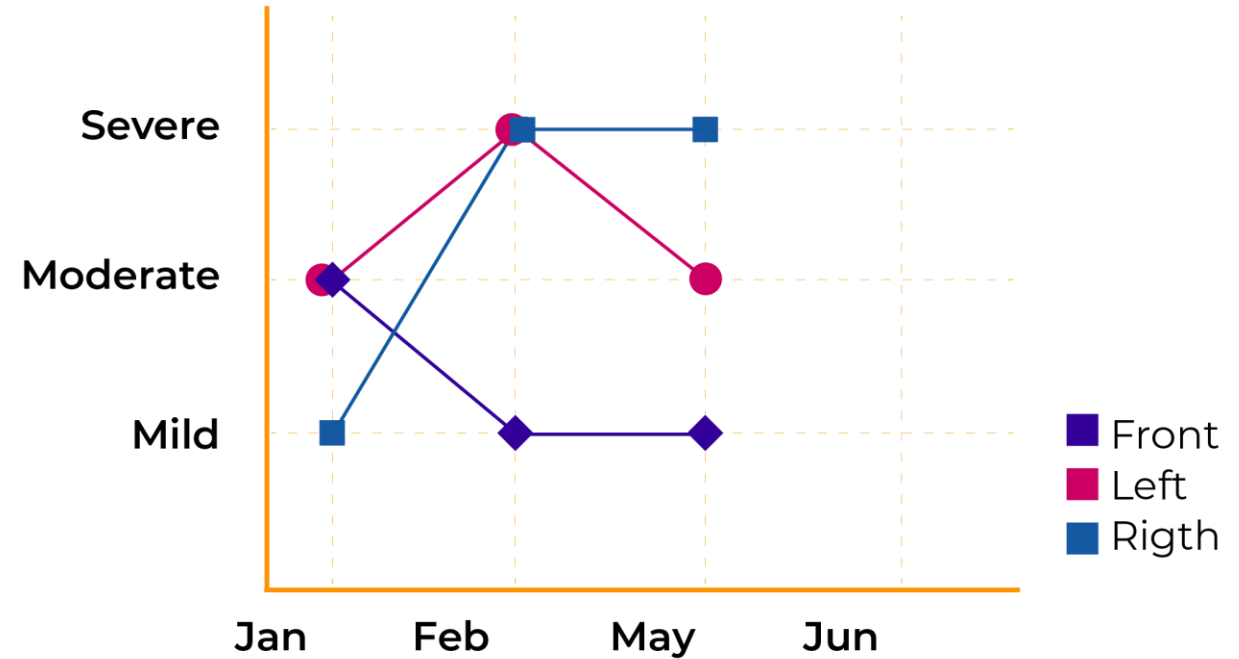

Tracking Acne Progress



Jan 2022 **Moderate** %4.24 **Moderate** %4.24 **Mild** %2.36

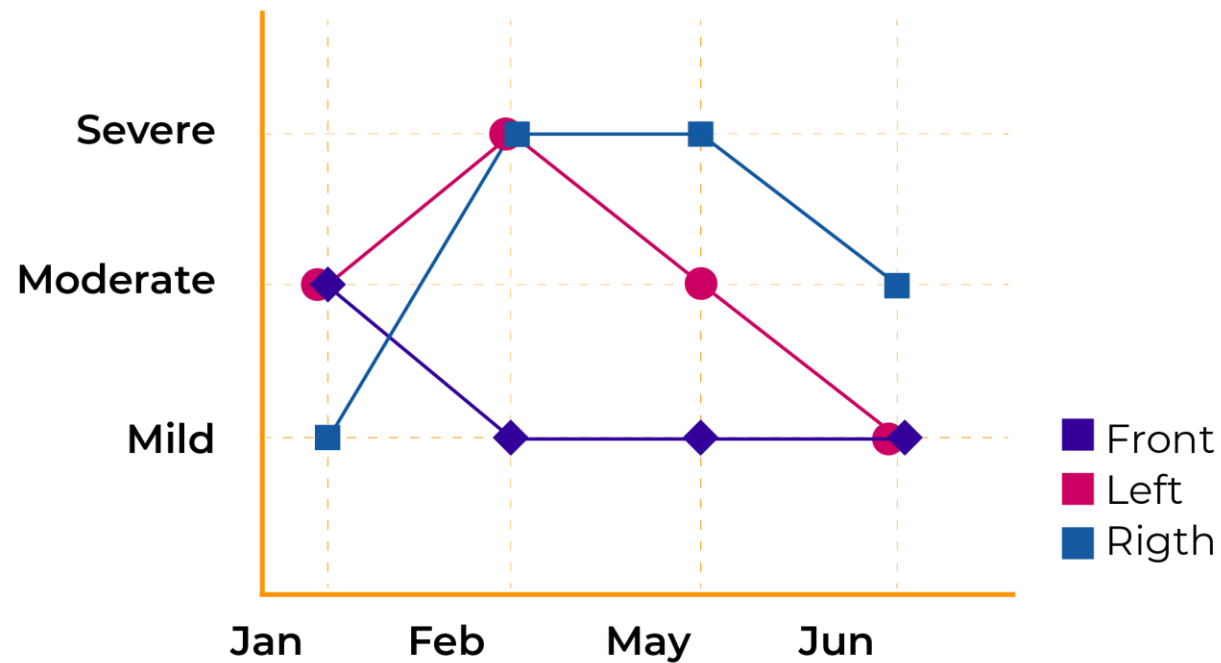

Feb 2022 **Mild** %3.21 **Severe** %3.89 **Severe** %5.34

Tracking Acne Progress



Jan 2022	Moderate %4.24	Moderate %4.24	Mild %2.36
Feb 2022	Mild %3.21	Severe %3.89	Severe %5.34
May 2022	Mild %3.82	Moderate %3.54	Severe %5.87

Tracking Acne Progress



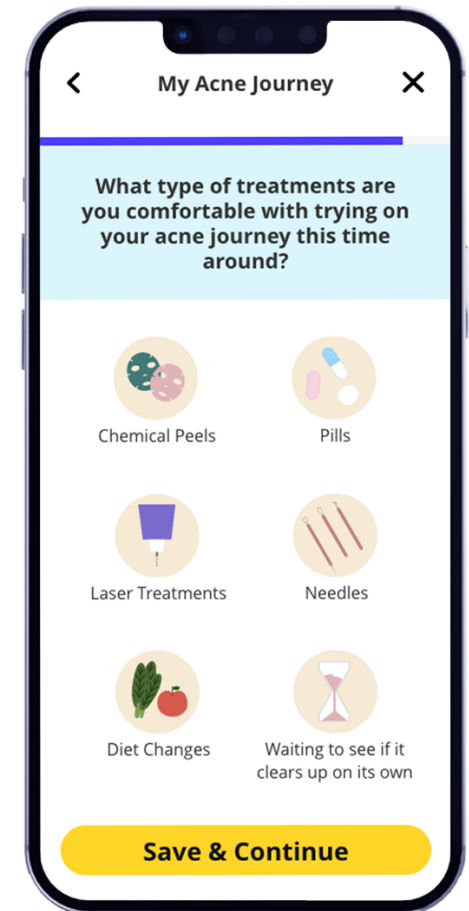
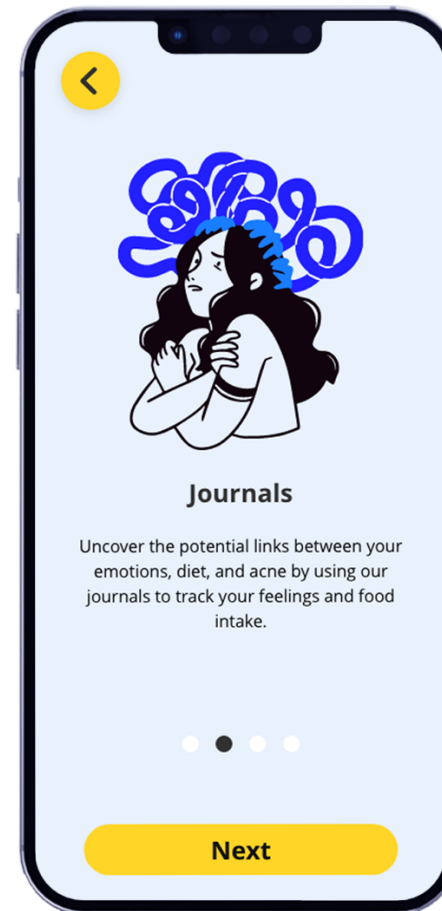
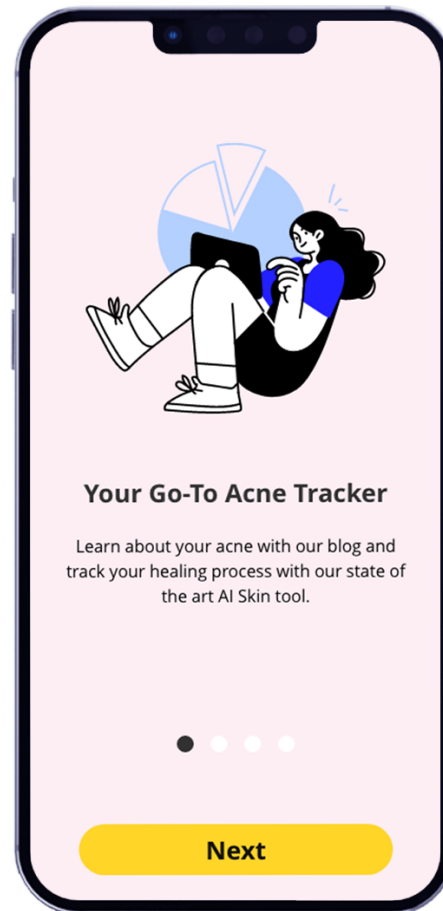
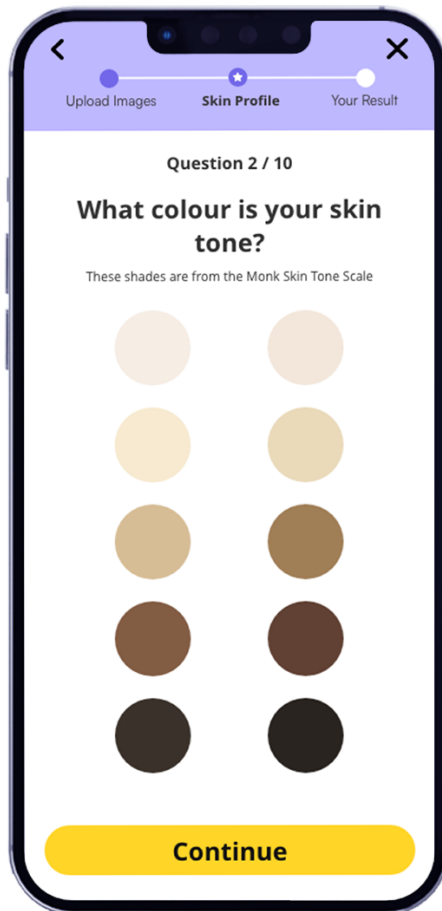
Jan 2022 **Moderate** %4.24 **Moderate** %4.24 **Mild** %2.36

Feb 2022 **Mild** %3.21 **Severe** %3.89 **Severe** %5.34

May 2022 **Mild** %3.82 **Moderate** %3.54 **Severe** %5.87

Jun 2022 **Mild** %2.79 **Mild** %4.72 **Moderate** %1.77

Treatment Adherence, Recommendation, and Education



SKINOPATHY



Algorithms + AI + Automation

- Maintenance therapy: After response is controlled, continue topical retinoid + BB treatment to prevent recurrence

4. Medications: General

4.1 Topical Treatments

Generic Name

Tretinoin

Adapalene

Tazarotene

Benzoyl Peroxide

Clindamycin
(Topical)

Azelaic Acid

✓ Most Commonly

4.2 Oral Antibiotics

Generic Name

Doxycycline

Minocycline

Tetracycline

✗ Avoid tetracycline

✓ Most Commonly

4.3 Hormonal Therapy

• Adjuncts:

- Topical Retinoids

- Benzoyl Peroxide

• If Refractory to Topical Therapy:

- Oral Isotretinoin

⚠ Caution:

- Avoid OCPs

- Monitor for side effects

2. Cystic Acne (Nodulocystic)

• Characteristics:

- Deep, painful nodules and cysts

- High risk of scarring

- Commonly found on the face, chest, and back

• First-Line Treatment:

✓ Oral Isotretinoin

- Most effective treatment

- Induces long-term remission

• Adjuncts Before and After:

- Oral Antibiotics

- Intralesional Corticosteroids

- Benzoyl Peroxide

⚠ Caution:

- Isotretinoin side effects

- Monitor for side effects

3. Adult Acne (Perioral)

• Characteristics:

Acne Vulgaris: Symptoms, Investigations, and Step-by-Step Treatment

Acne vulgaris is a **chronic inflammatory skin condition** involving the **pilosebaceous unit**, characterized by comedones, papules, pustules, nodules, and cysts. It affects adolescents but can persist into adulthood, with varying lesion types.

1. Symptoms and Signs

Symptoms

- Facial, chest, and back

- Painful nodules and cysts

- Post-inflammatory hyperpigmentation

- Fluctuating course

Signs (Types of Acne Lesions)

Type

Comedonal Acne

Inflammatory Acne

Nodulocystic Acne

Acne Conglobata

Acne Fulminans

2. Diagnostic Investigations

Step 1: Clinical Diagnosis

- Acne is diagnosed clinically

- Consider differential diagnosis

Acne vulgaris



Acne vulgaris is a common chronic



**JOIN US
TO REVOLUTIONIZE
THE FUTURE OF ACNE**

SKIN**PATHY**

Keith Loo

keith@skinopathy.com

(437) 887-8686